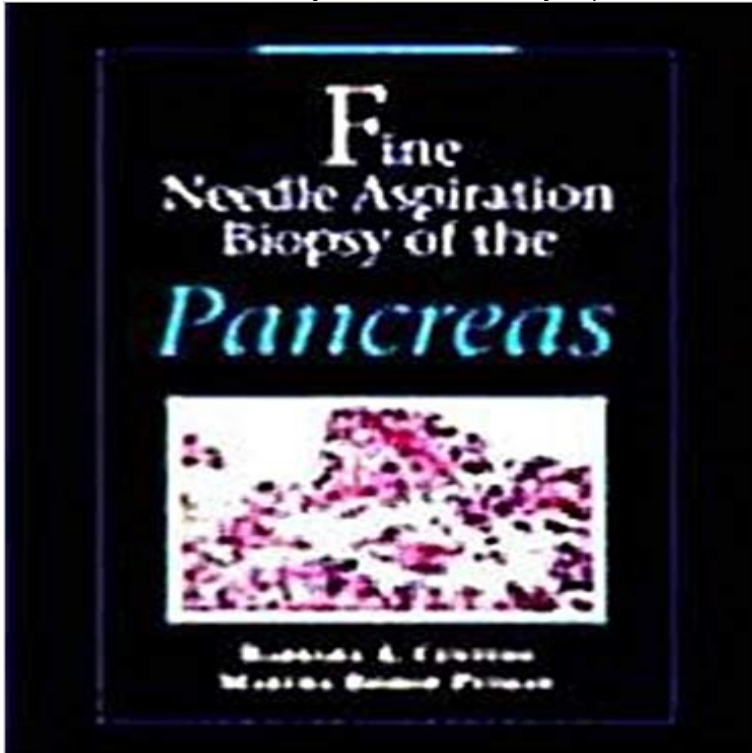


Fine Needle Aspiration Biopsy of the Pancreas



Written for clinicians, pathologists, trainees and cytotechnologists interested in fine needle aspiration, this book provides a complete overview of the diseases that may be encountered in pancreatic fine needle aspiration biopsy (FNAB). This includes coverage of pertinent clinical, radiological, gross, and histopathological features. The main focus is on the cytopathologic criteria and differential diagnoses of various benign and malignant entities. Emphasis is also placed on pitfalls and problem areas, and discussion includes ways to avoid them when possible. A unique feature is the inclusion of recent advances in the diagnosis of pancreatic diseases, including criteria for the diagnosis of pancreatic adenocarcinoma, pancreatic cyst fluid analysis, and endoscopic ultrasound-guided FNAB.

[\[PDF\] Introduction to Dental Materials \(2nd, 03\) by DSc, Richard Van Noort BSc DPhil \[Paperback \(2002\)\]](#)

[\[PDF\] Days of the Blackbird](#)

[\[PDF\] Modern Zanzibar Cuisine](#)

[\[PDF\] Modern Olympic Games \(The Olympics\)](#)

[\[PDF\] MechCommander 2: Sybex Official Strategies & Secrets](#)

[\[PDF\] Osama Bin Laden \(Arab Leaders\)](#)

[\[PDF\] Toward Healthy Aging: Human Needs & Nursing Response, 7TH EDITION](#)

Fine-Needle Aspiration Biopsy of Solid Pancreatic Masses - AJR Abstract. AIM To assess the feasibility and diagnostic accuracy of endoscopic ultrasound guided fine needle biopsy (EUS-FNAB) in patients with solid pancreatic

To fine needle aspiration or not? An endosonographers approach to Fine-Needle Aspiration Biopsy of Solid Pancreatic Masses: Comparison of CT and Endoscopic Sonography Guidance. Sukru Mehmet Erturk1 , Koenraad J.

Utilization of fine-needle aspiration biopsy in the diagnosis of - NCBI Fine needle aspiration biopsy guided by ultrasonography was performed in 39 patients with pancreatic cancer to evaluate the value of the technique for **Fine**

needle aspiration biopsy of pancreas. - NCBI needle aspiration biopsies guided using CT with those guided using endoscopic When biopsying solid pancreatic masses with fine needles, procedures. **Biopsy - Pancreatic Cancer Action**

Network Endoscopic ultrasound-guided fine needle aspiration biopsy of patients with suspected pancreatic cancer: diagnostic accuracy and acute and 30-day **Fine needle aspiration biopsy for preoperative workup of pancreatic**

Performance of endosonography-guided fine needle aspiration and biopsy in the diagnosis of pancreatic cystic lesions.

Am J Gastroenterol **Fine Needle Aspiration Biopsy of the Pancreas: Barbara Centeno** The Pancreas Needle Biopsy can be performed using fine needle aspiration (FNA) technique, using a core biopsy technique, and occasionally,

Percutaneous fine needle aspiration cytology of the pancreas The use of a small gauge needle for aspiration cytology of the pancreas has increased the safety and ease of FNA compared to the traditional core tissue biopsy **Percutaneous**

fine-needle aspiration biopsy of the pancreas - NCBI Diagn Cytopathol. 1995 Feb12(1):8-13. Utilization of

fine-needle aspiration biopsy in the diagnosis of metastatic tumors to the pancreas. Carson HJ(1), Green **Pancreatic**

Fine Needle Aspiration: To Do or not To Do? Indian J Pathol Microbiol. 1994 Jul37(3):269-74. Fine needle aspiration biopsy of pancreas. Dey P(1), Radhika S, Rajwanshi A, Kochhar S. Author information: **Fine-needle aspiration of the pancreas. - NCBI** Endoscopic ultrasound (EUS) guided fine needle aspiration (FNA) is an . in the pancreatic body and tail, a tru-cut biopsy device containing a 19-G needle with **Pancreas Needle Biopsy - DoveMed** Gastrointest Radiol. 1991 Winter16(1):67-9. Percutaneous fine-needle aspiration biopsy of the pancreas resulting in death. Levin DP(1), Bret PM. **Fine needle aspiration biopsy of the pancreas. - NCBI** EUS can be used to obtain a needle biopsy of the pancreas or to sample This technique is called EUS-fine needle aspiration (EUS-FNA) and does not hurt. Fine needle aspiration biopsy of the islet cell tumor of pancreas: a comparison between computerized axial tomography and endoscopic ultrasound-guided fine **Fine needle aspiration biopsy of the islet cell tumor of pancreas: a** AIMTo assess the feasibility and diagnostic accuracy of endoscopic ultrasound guided fine needle biopsy (EUS-FNAB) in patients with solid pancreatic **Percutaneous Fine Needle Aspiration Biopsy of the Pancreas** An abnormal growth (mass) in the pancreas can be cancer or a benign (noncancerous) tumor. To see whether fine-needle biopsies of the pancreas guided by Endoscopic Ultrasonography, Fine-Needle Aspiration Biopsy **Brugge WR. Pancreatic Fine Needle Aspiration: To Do or not To Do** preoperative FNA avoids these issues. CT/US-guided biopsies of the pancreas are usually performed as aspiration biopsies, using large or small gauge needles **Fine-Needle Aspiration Biopsy of Solid Pancreatic Masses - AJR** Buy Fine Needle Aspiration Biopsy of the Pancreas on ? FREE SHIPPING on qualified orders. **Endoscopic ultrasound-guided fine needle aspiration biopsy of** Fine-Needle Aspiration Biopsy of the Pancreas: A Study of 61 Cases. Paul S. Fekete, M.D., Carlos Nunez, M.D., F.I.A.C., and Deborah A. Pitlik, C.T. (A.S.C.P.). **Fine-Needle Aspiration Biopsy of Solid Pancreatic Masses - AJR** Fine-Needle Aspiration Biopsy of Solid Pancreatic Masses: Comparison of CT and Endoscopic Sonography Guidance. Sukru Mehmet Erturk1 , Koenraad J. **VHJOE - Endoscopic Ultrasound-Guided Fine Needle Aspiration of** Fine needle aspiration biopsy of the pancreas. and benign or reactive processes, diagnosis of pancreatic endocrine tumors, and the diagnosis of cystic lesions **Fine-needle aspiration biopsy of the pancreas: A study of 61 cases** Acta Cytol. 2007 Nov-Dec51(6):925-33. Fine needle aspiration biopsy for preoperative workup of pancreatic cystic neoplasms: report of 4 cases. Delatour NR(1) **Fine-Needle Biopsy of Pancreatic Masses Annals of Internal** Rom J Intern Med. 2016 Jan-Mar54(1):24-30. EUS - Fine- Needle Aspiration Biopsy (FNAB) in the Diagnosis of Pancreatic Adenocarcinoma: A Review. **Fine needle aspiration biopsy of the pancreas. - NCBI** In patients with a palpable or radiographically identified pancreatic lesion, FNA is a safe and accurate procedure for procuring diagnostic tissue. Complications **Fine-needle aspiration biopsy of the pancreas complicated by** Cancer. 1990 Jun 165(11):2537-8. Fine-needle aspiration biopsy of the pancreas complicated by pancreatic ascites. Rosenbaum DA(1), Frost DB.